




Contents lists available at ScienceDirect

European Journal of Radiology

journal homepage: www.elsevier.com/locate/ejrad



Usefulness of US-CT 3D dual imaging for the planning and monitoring of hepatocellular carcinoma treatment using HIFU

Hiroyuki Fukuda^{a,*}, Kazushi Numata^a, Akito Nozaki^a, Manabu Morimoto^a, Masaaki Kondo^a, Katsuaki Tanaka^a, Shin Maeda^a, Jin Yamagata^b, Masao Ohto^c, Ryu Ito^c, Akio Sakamoto^c, Hui Zhu^d, Zhi-Biao Wang^e

^a Gastroenterological Center, Yokohama City University Medical Center, 4-57 Urafune-cho, Minami-ku, Yokohama, Kanagawa 232-0024, Japan

^b Toshiba Medical Systems Corporation, Otawara, 324-0036, Japan

^c International HIFU Center, Naruto General Hospital, Naruto 167, Sanbu-shi, Chiba 289-1326, Japan

^d Clinical Center of Tumor Therapy of 2nd Affiliated Hospital, Chongqing University of Medical Sciences, Chongqing, PR China

^e Institute of Ultrasonic Engineering in Medicine, Chongqing University of Medical Sciences, Chongqing, PR China

ARTICLE INFO

Article history:

Received 9 August 2010

Accepted 28 December 2010

Keywords:

US-CT 3D dual imaging
Hepatocellular carcinoma
HIFU

ABSTRACT

Purpose: We evaluated the safety and usefulness of high-intensity focused ultrasound (HIFU) assisted by ultrasound-computed tomography three-dimensional (US-CT 3D) dual imaging for the treatment of hepatocellular carcinoma (HCC).

Materials and methods: HIFU ablation was performed in 13 patients with small HCC (≤ 3 lesions, ≤ 3 cm in diameter). The HIFU system (Chongqing Haifu Tech) was used under ultrasound guidance. By transferring the sagittal or axial plane of the 3D US and the CT volume data into the ZioM900, multiplanar reconstruction images were displayed in a manner resembling conventional monitor US to assist the HIFU treatment.

Results: Overall, 69% (9/13) of the patients in whom good visualization using B-mode sonography could not be obtained because of the influence of multi-reflections, rib shadows, and unclear tumor margins were successfully treated under the guidance of US-CT 3D dual imaging. In 5 of the 13 patients, multi-reflections were responsible for the poor visualization. In 2 cases, the tumor was poorly visualized because of a rib shadow. In one case, the margin of the tumor was too unclear to be detected using ultrasonography. The 3D US images obtained as part of the US-CT 3D dual imaging had a high resolution and were useful for examining the area of HCC invasion and for determining the extent of the ablation area. The CT images, which are not influenced by bone shadows or multi-reflections, were useful for detecting the tumors and for visualizing the presence of the intestines in the sonication zone. HIFU treatments were successfully performed in all the patients with the assistance of US-CT 3D dual imaging.

Conclusion: US-CT 3D dual imaging is useful for HIFU treatment for HCC, compensating for the occasionally poor visualization provided by US monitor.

© 2011 Elsevier Ireland Ltd. All rights reserved.

1. Introduction

Hepatocellular carcinoma (HCC) is one of the most common malignancies in the world. A variety of nonsurgical procedures, such as percutaneous ethanol injection (PEI) [1,2] and microwave [3,4] and radiofrequency ablation (RFA) [5,6], have been widely used for the treatment of small hepatocellular carcinoma (HCC) patients who are not candidates for surgery [7–9]. High-intensity focused ultrasound (HIFU) is a noninvasive treatment method, as

complete coagulation necrosis is achieved without the insertion of any instruments [10–16].

B-mode conventional sonography is used to monitor the HCC during HIFU treatment, but tumors located below the diaphragm or deep within the liver are often obscured on conventional monitor sonography. In addition, smaller HCCs cannot be detected clearly on conventional monitor sonography.

Three-dimensional (3D) sonography is reportedly useful for the detection of tissue structures and the diagnosis of small lesions [17,18]. These previous reports have indicated a good correlation between contrast-enhanced 3D sonography and histological findings. Although sonography has the disadvantage that it cannot depict a wide area without being influenced by air and bone, computed tomography (CT) can visualize a wide area. Recent advances

* Corresponding author. Tel.: +81 45 261 5656; fax: +81 45 261 9492.
E-mail address: fukuhiro1962@hotmail.com (H. Fukuda).

Table 1
Baseline clinical characteristics of patients with hepatocellular carcinoma ($n = 13$).

Characteristics	
Number of patients	13
Sex (male/female)	6/7
Age	73.2 ± 6.5 (63–80)
Alcohol/HCV/HBsAg	1/12/0
Child A/B/C	8/6/0
Diameter	16.5 ± 3.6 (10–23)
Rt/Lt	6/7

in CT have enabled the synthesis of high-quality multiplanar reconstruction (MPR) images. US-CT 3D dual imaging is a diagnostic imaging support system that can provide the same cross-sectional MPR images on the same monitor screen using DICOM (Digital Imaging and Communication in Medicine) volume data from 3D US and 3D CT.

The purpose of the present study was to evaluate the safety and usefulness of HIFU assisted by US-CT 3D dual imaging for the treatment of HCC.

2. Materials and methods

2.1. Patients

Between July 2006 and July 2008, 13 patients with HCC were enrolled in this clinical study. Table 1 summarizes the baseline characteristics of the treated patients. The patients consisted of 6 men and 7 women, with a mean age of 73.2 ± 6.5 years (mean ± SD). The average tumor diameter was 16.5 ± 3.6 mm (mean ± SD). The diagnosis of hepatocellular carcinoma was confirmed by percutaneous needle biopsy in 2 tumors. The remaining 11 tumors were diagnosed as hepatocellular carcinomas based on imaging findings (contrast-enhanced multiphase helical computed tomography [CT]). Thirteen patients had liver cirrhosis as a result of hepatitis C ($n = 12$) or alcoholism ($n = 1$). At the time of HIFU, 8 and 5 patients had Child-Pugh classifications A and B, respectively. Prior to treatment, the patient's skin was shaved and degassed. Epidural anesthesia was performed during the procedure. Our hospital ethics committee approved this study, and each patient signed an informed consent form at the time of enrollment.

2.2. Ultrasound therapy system

Sonications were performed using a clinical US guided ultrasound surgery system. The Tumor Therapy System (Chongqing Haifu Tech Co., Ltd., Chongqing, China) used in this study was guided using real-time ultrasonographic imaging [11–14]. An HIFU 6150S US imaging unit was installed on the HIFU system to obtain real-time US imaging during HIFU ablation. A 2–5-MHz imaging probe was positioned in the center of the HIFU transducer and was mounted in a reservoir of degassed water [11–14]. The therapeutic US energy was produced by an HIFU transducer with a 1.0 MHz operating frequency. After suitable anesthesia was induced, the patient was carefully positioned, either prone or on his or her right side, so that the skin overlying the lesion to be treated could be easily placed in contact with the degassed water. During the focused ultrasound ablation of each section, the real-time US images obtained before and after each exposure were immediately compared to determine whether the echogenic changes, indicating the extent of coagulation necrosis, had covered the desired treatment area [11–14]. Patients were trained to hold their breath in a repeated manner when the tumor was situated behind a rib.

Table 2
US detection and causes of the poor visibility.

US detection	Cause of poor visibility	
Clear		4
Poor	Multi-reflection	5
	Rib shadow	3
	Unclear tumor margin	1

2.3. Ultrasound imaging

3D volume data from ultrasonography (Aplio™; Toshiba Medical Systems Corp., Tokyo, Japan) was obtained using free-hand tilt scanning with a convex type probe equipped with a 3D sensor while the patients held their breaths for 10–12 s [17,18]. The imaging parameters employed for 3D gray scale US imaging were a transmission frequency of 3.2 MHz, a mechanical index (MI) of 1.6, and an acquisition rate of 19 frames/s and a gain of 84 [17,18].

2.4. CT imaging

Triple-phase helical CT was performed after overnight fasting with the patient in a spinal position using a CT scanner (Light Speed Ultra, GE Medical Systems, Milwaukee, WI, USA). Contrast medium (Iopamiron; Bracco, Milan, Italy) was injected intravenously. The scanning parameters were as follows: 1.25 mm collimation × 16, pitch of 0.63, 140 kVp, 280 mA, 512 × 512 matrix, 1.25 mm reconstruction thickness.

2.5. US-CT 3D dual imaging

The 3D US volume data were obtained while the patient was in the same spine position and with breezing-in when the CT scan was performed. The 3D raw data obtained using ultrasonography were converted to DICOM data using Echo to CT (Toshiba Medical Systems Corp., Tokyo, Japan) and sent to the ZioM900 (ZIOSOFT Inc., Tokyo, Japan). 3D CT DICOM data were sent to the ZioM900 directly. By setting the 3D CT plane as the axial or sagittal plane of the 3D US on the ZioM900, MPR images of 3D CT were displayed in a shape resembling conventional monitor US. To adjust for minute differences in the planes between the CT and US images, the intra-hepatic portal vein, hepatic vein, gallbladder and diaphragm were used as markers. The 3D images were observed stereoscopically while using opacity control and plane shifting.

3. Results

Table 2 summarize US monitor detection and causes of the poor visibility. Overall, the lesions in 69% (9/13) of the patients could not be adequately visualized using B-mode monitor sonography. The reasons for the poor visualization included the influence of multi-reflections, rib shadows, and an unclear tumor margin. In 5 of the 13 patients, multi-reflections were responsible for the poor visualization. In 2 cases, the tumor was poorly visualized because of a rib shadow. In one case, the margin of the tumor was too unclear to be detected using ultrasonography. In these patients, the CT images, which are not influenced by bone shadows or multi-reflections, were useful for tumor detection. In these cases, it was very useful to detect the tumor on the monitor by referencing the distance of the tumor from the main portal vein and the hepatic vein using US-CT 3D dual imaging. Finally, HIFU treatment assisted by US-CT 3D dual imaging was successfully performed in all the patients.

Representative cases of US-CT 3D dual imaging in patients with HCC are presented in Figs. 1 and 2. The tumor on the monitor ultrasonogram was not clearly visible because of the presence of

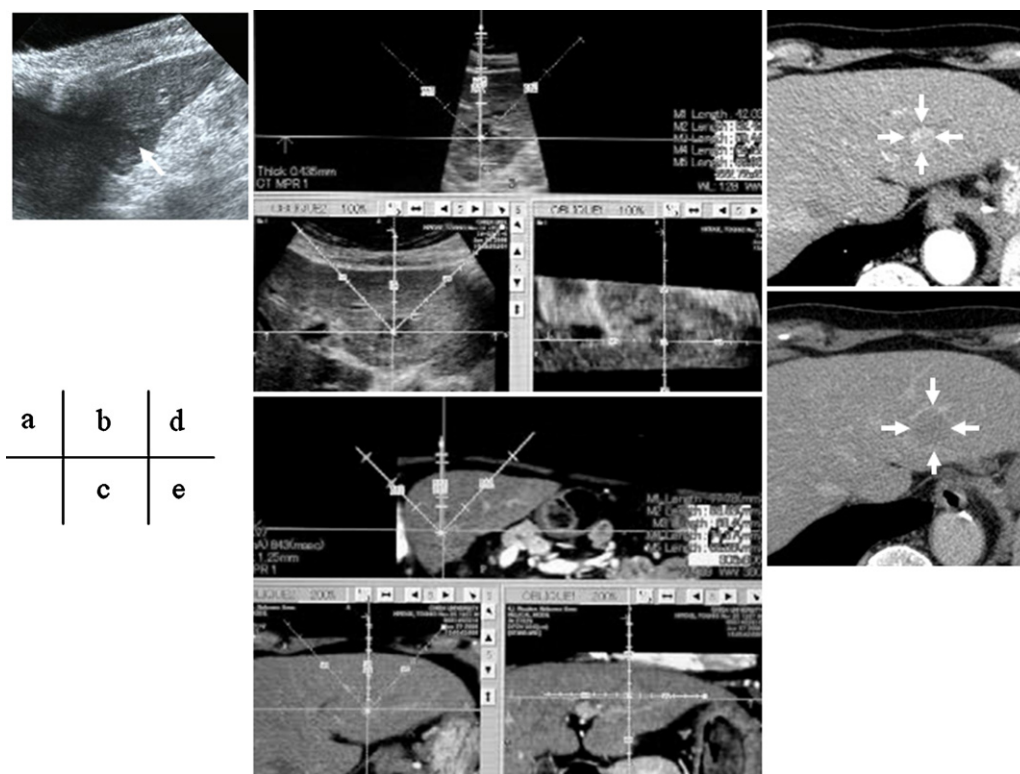


Fig. 1. A 78-year-old male patient with an HCC. (a) Monitor ultrasonography. The tumor (arrow) was not clearly visible because of multi-reflections. (b) The 3D US images obtained as part of US-CT 3D dual imaging were useful for examining the area invaded by the HCC and for determining the extent of the ablation area. (c) 3D CT images obtained as part of US-CT 3D dual imaging were useful for checking the safety of the procedure by enabling the presence of intestines and lung gas to be identified in the sonication zone (dotted line). (d) Tumor staining was visible on the CT scan during the arterial phase (arrow). (e) CT assessment after HIFU ablation. After treatment, the tumor staining disappeared from the CT scan obtained during the equilibrium phase (arrow).

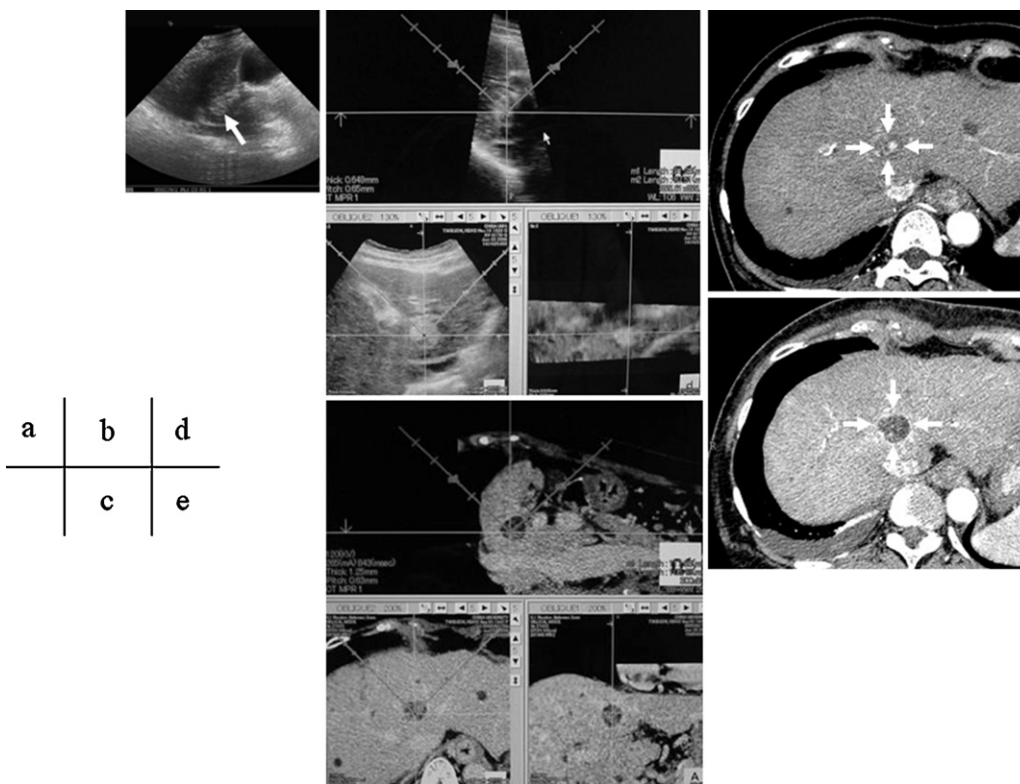


Fig. 2. A 63-year-old female patient with an HCC. (a) The tumor (arrow) was not depicted clearly on the monitor. (b) 3D ultrasonogram. (c) 3D CT images obtained as part of the US-CT 3D dual imaging were useful for confirming the safety in the sonication zone (dotted line). (d) CT scan during the arterial phase before HIFU ablation (arrow). (e) The area of ablation is visible as a very low-density area after HIFU treatment on the CT scan obtained during the arterial phase (arrow).

multi-reflections. By transferring the sagittal or axial plane of 3D CT volume data to the ZioM900, MPR images of 3D US and CT were displayed in a shape resembling conventional US on the HIFU monitor (Fig. 1b and c). The 3D US images obtained as part of US-CT 3D dual imaging had a high resolution and were useful for examining the area of HCC invasion and for determining the extent of the ablation area. On the other hand, the 3D CT images obtained as part of US-CT 3D dual imaging were useful for confirming the safety of the procedure by enabling the presence of intestines and lung gas to be detected in the sonication zone, since CT can depict a wide area. The tumor staining successfully disappeared after treatment. In another case, the tumor on the monitor was not depicted clearly because the tumor was located deep within the liver and multi-reflection interference was present (Fig. 2). The 3D US images obtained as part of US-CT 3D dual imaging were useful for depicting the margin of HCC and for determining the extent of the ablation area. Meanwhile, the 3D CT images obtained as part of US-CT 3D dual imaging were useful for confirming the safety of the procedure. The ablated area after HIFU ablation was thought to be sufficiently wide.

4. Discussion

In recent years, numerous type of 3D software to analyze CT, MRI and US images have been developed for clinical use [19–22]. In this study, US-CT 3D dual imaging was used to depict the same section of US and CT images, and the utility of this modality for planning HIFU for the treatment of HCC was evaluated. The poor visualization using HIFU monitor is caused by the presence of the multi-reflections, rib shadows and the unclear tumor margins. Tumors located deep within the liver are easily influenced by multi-reflections. The another reason for the poor visualization using HIFU machine is thought to be that US monitor is designed with the assumption that the US probe will not touch the skin to protect the US probe from the HIFU power during HIFU sonication and the presence of degassed water between the skin and the US probe.

US has a high resolution for depicting minute lesions but is easily influenced by several factors, such as lung shadow, rib shadow, intestinal gas and multi-reflections. On the other hand, CT can depict a wide area without any influence from these factors. Depending on whether the US images are obtained in a sagittal or axial plane during the treatment of hepatocellular carcinoma, the 3D CT image slices are obtained sagittally or axially, respectively. By entering the angle number of the 3D volume data into the ZioM900, MPR images of the CT data were easily displayed in a shape resembling conventional US. To adjust for minute differences in the planes between the CT and US images, the intrahepatic portal vein, hepatic vein, gallbladder and diaphragm were used as markers. We are able to use opacity control and plane moving because 3D volume data was available for both CT and US images. The difference between real time virtual sonography (RVS) (Hitachi Co., Tokyo) [23–26], a similar modality to make the same plane of the CT and US images, and 3D dual imaging is that RVS is simulated the same plane of both the US and CT images simultaneously and is useful for ablation planning. The detectability of 3D US was superior to that of two-dimensional (2D) US [17,18], so 3D US images are thought to be more useful for the diagnosis of small minute lesions because 3D US images contain 3D volume data, unlike 2D US data obtained using RVS. The reason for this higher detectability of 3D US imaging is thought to be the availability of opacity control and plane shifting. Although the high resolution of 3D US is advantageous, it cannot depict a wide area, compared with CT scans. So, the combination of CT and US was expected to be useful for planning the extent of the ablated area and to ensure the safety of the procedure.

US-CT dual imaging was not used for the needle puncture in the present study, so we think that simultaneous movement is not necessary.

When the tumor was not depicted clearly on the monitor display, we used 3D CT volume data to detect the tumor first. Then, we calculated the distance between the tumor and the main internal indicators, such as the portal vein, gallbladder and hepatic vein, using the CT volume data. Next, we depicted the internal indicators on the US monitor display and move the US probe the distance calculated on the CT scan. As the tumor was thought to exist around this location, we examined this area carefully or touched the US probe to the skin if multi-reflections interfered with the tumor image. In this manner, all the tumors in this study were successfully detected and treated.

During the follow-up period after HIFU treatment, only one local recurrence occurred. The patient with the local recurrence had difficulty remaining in the correct position and the procedure lasted for a relatively long time, so it was very difficult to obtain a wide safety margin. No severe complications were detected during the follow-up period. This study was limited in that only a small number of cases was examined. Further study is needed to determine the usefulness of US-CT 3D dual imaging conclusively.

In conclusion, US-CT 3D dual imaging is useful for planning the extent and safety of HIFU for HCC.

References

- [1] Bartolozzi C, Lencioni R. Ethanol injection for the treatment of hepatic tumors. *Eur Radiol* 1996;6:682–96.
- [2] Lencioni R, Caramella D, Bartolozzi C. Hepatocellular carcinoma: use of color Doppler US to evaluate response to treatment with percutaneous ethanol injection. *Radiology* 1995;194:113–8.
- [3] Matsukawa T, Yamashita Y, Arakawa A, et al. Percutaneous microwave coagulation therapy in liver tumors: a 3-year experience. *Acta Radiol* 1997;38:410–5.
- [4] Sato M, Watanabe Y, Kashu Y, et al. Sequential percutaneous microwave coagulation therapy for liver tumor. *Am J Surg* 1998;175:322–4.
- [5] Gazelle GS, Goldberg SN, Solbiati L, Livraghi T. Tumor ablation with radiofrequency energy. *Radiology* 2000;217:633–46.
- [6] McGahan JP, Dodd GD. Radiofrequency ablation of the liver: current status. *Am J Roentgenol* 2001;176:3–16.
- [7] Lin D, Lin SM, Liaw YF. Non-surgical treatment of hepatocellular carcinoma. *J Gastroenterol Hepatol* 1997;12:S319–28.
- [8] Lin TY, Lee CS, Chen KM, Chen CC. Role of surgery in the treatment of primary carcinoma of the liver: a 31-year experience. *Br J Surg* 1987;74:839–42.
- [9] Zibari GB, Riche A, Zizzi HC, et al. Surgical and nonsurgical management of primary and metastatic liver tumors. *Am Surg* 1998;64:211–21.
- [10] ter Haar G. High intensity ultrasound. *Semin Laparosc Surg* 2001;8:77–89.
- [11] Wu F, Chen WZ, Bai J, et al. Pathological changes in human malignant carcinoma treated with high-intensity focused ultrasound. *Ultrasound Med Biol* 2001;27:1099–106.
- [12] Wu F, Wang ZB, Cao YD, et al. A randomised clinical trial of high-intensity focused ultrasound ablation for the treatment of patients with localised breast cancer. *Br J Cancer* 2003;89:2227–33.
- [13] Wu F, Wang ZB, Chen WZ, et al. Extracorporeal high intensity focused ultrasound ablation in the treatment of patients with large hepatocellular carcinoma. *Ann Surg Oncol* 2004;11:1061–9.
- [14] Wu F, Wang ZB, Zhu H, et al. Advanced hepatocellular carcinoma: treatment with high-intensity focused ultrasound ablation combined with transcatheter arterial embolization. *Radiology* 2005;235:659–67.
- [15] Hynynen K, Pomeroy O, Smith DN, et al. MR imaging-guided focused ultrasound surgery of fibroadenoma in the breast: a feasibility study. *Radiology* 2001;219:176–85.
- [16] Jolesz FA, Hynynen K, McDannold N, Freundlich D, Kopelman D. Non-invasive thermal ablation of hepatocellular carcinoma by using magnetic resonance imaging-guided focused ultrasound. *Gastroenterology* 2004;127:S242–7.
- [17] Ohto M, Kato H, Tsujii H, et al. Vascular flow patterns of hepatic tumors in contrast-enhanced three-dimensional fusion ultrasonography using plane shift and opacity control modes. *J Ultrasound Med* 2005;24:49–57.
- [18] Yukisawa S, Ohto M, Masuya Y, et al. Contrast-enhanced three-dimensional fusion sonography of small liver metastases with pathologic correlation. *J Clin Ultrasound* 2007;35:1–8.
- [19] Xu HX, Yin XY, Lu MD, et al. Usefulness of three-dimensional sonography in procedures of ablation for liver cancers. *J Ultrasound Med* 2003;22:1239–47.
- [20] Xu HX, Liu L, Lu MD, et al. Three-dimensional power Doppler imaging in depicting vascularity in hepatocellular carcinoma. *J Ultrasound Med* 2003;22:1147–54.

- [21] Schroeder T, Nadalin S, Stattaus J, et al. Potential living liver donors: evaluation with an all-in-one protocol with multi-detector row CT. *Radiology* 2002;224:586–91.
- [22] Shinozaki K, Honda H, Yoshimitsu K, et al. Optimal multi-phase three-dimensional fast imaging with steady-state free precession dynamic MRI and its clinical application to the diagnosis of hepatocellular carcinoma. *Radiat Med* 2002;20:111–9.
- [23] Hirooka M, Iuchi H, Kurose K, et al. Abdominal virtual ultrasonographic images reconstructed by multi-detector row helical computed tomography. *Eur J Radiol* 2005;53:312–7.
- [24] Tatsugami F, Matsuki M, Nakai G, et al. Hepatic computed tomography for simultaneous depiction of hepatocellular carcinoma, intrahepatic portal vein, and hepatic veins in real-time virtual sonography: initial experience. *J Ultrasound Med* 2007;26:1065–9.
- [25] Minami Y, Chung H, Kudo M, et al. Radiofrequency ablation of hepatocellular carcinoma: value of virtual CT sonography with magnetic navigation. *AJR* 2008;190:W335–341.
- [26] Nakai M, Sato M, Sahara S, et al. Radiofrequency ablation assisted by real-time virtual sonography and CT for hepatocellular carcinoma undetectable by conventional sonography. *Cardiovasc Intervent Radiol* 2009;32:62–9.